

Brucella Spondylodiscitis: A Case Report of Pediatric Spinal Brucellosis in a 2 year Old Child

M.M Ramdas^a, Nihala N K^a, Jayakrishnan^b, Manuel J^c

a. Department of Pediatrics, E.M.S Memorial Co-operative Hospital and Research Centre, Perinthalmanna, Malappuram, Kerala;

b. Department of Neurosurgery, E.M.S Memorial Co-operative Hospital and Research Centre, Perinthalmanna, Malappuram, Kerala;

c. Department of Orthopedics, E.M.S Memorial Co-operative Hospital and Research Centre, Perinthalmanna, Malappuram, Kerala.*

ABSTRACT

Published on 30th March 2026

Brucella spondylodiscitis is one of the most commonly encountered localised form of human brucellosis and the major cause of debilitating and disabling complication. Most commonly, lumbar vertebrae are involved. A 2-year-old child presented with low backache associated with difficulty in walking of 2 months duration. She showed gibbus deformity and tenderness at the level of L2-L3 vertebrae. CBNAAT test for tuberculosis was negative. MRI spine revealed diffuse marrow edema of L2-L3 vertebral bodies with reduced L2-L3 disc height. Serological workup showed positive ELISA Brucella antibody IgM titre 1.20. She was treated with IV amikacin for 10 days, oral Rifampicin for 6m and oral Cotrimoxazole for 6 weeks. Repeat imaging after 8 weeks revealed regression of the disease. Followup showed complete clinical and radiological recovery after 6 months. In endemic regions, brucella spondylodiscitis should be considered in patients with back pain with or without neurological deficits. Early and rapid diagnosis and long term antibrucellar antibiotic treatment gives complete recovery.

Keywords: Brucella Spondylodiscitis, Lumbar Vertebrae, MRI

*See End Note for complete author details

INTRODUCTION

Brucellosis is an important yet neglected zoonotic disease in India. Consumption of unpasteurized milk represents a common source of indirect transmission. Direct transmission may occur through close contact with animal carrying Brucella. Brucellosis is a systemic disease which may affect many organ systems. Focal involvement in brucellosis occurs in 10-85% of cases, mainly musculoskeletal system. Spondylodiscitis is one of the most commonly encountered localised form of human brucellosis and the major cause of debilitating and disabling complication. Lumbar vertebrae are more frequently involved. Blood culture of a patient provides definite proof of brucellosis. However, cultures are rarely positive before one to 3 weeks of incubation. The Brucella ELISA test has been reported to be rapid, highly sensitive and specific for detecting the Brucella-specific antibodies. IgM anti-brucella antibodies are indicative of acute or recent infection. The

modern semi-automatic blood culture systems such as BACTEC have markedly improved the speed of detection and aids in rapid diagnosis. Herein we report a case of brucella spondylodiscitis in 2y old boy completely cured with medical treatment.

CASE REPORT

A 2-year-old child presented with history of low backache since past 2 months associated with difficulty in walking and weight bearing on lower limbs. History low grade fever was present. Personal history revealed consumption of dairy products from unpasteurized cow and camel milk in recent past, history of travel to Middle East country was present.

On examination at admission child was conscious, oriented and vitals were stable. Systemwise examination revealed gibbus at the level of L2-L3 associated with moderate tenderness. Bilateral lower limb deep

Cite this article as: Ramdas MM, Nihala NK, Jayakrishnan J, Manuel J. Brucella Spondylodiscitis: A Case Report of Pediatric Spinal Brucellosis in a 2-Year-Old Child. Kerala Medical Journal. 2026 Mar 30;19(1):34-36.

Corresponding Author:

Dr. M.M Ramdas, Department of Pediatrics, E.M.S Memorial Co-operative Hospital and Research Centre, Perinthalmanna, Malappuram, Kerala, India. E-mail: mmramdas12@gmail.com Mobile: 9447832631

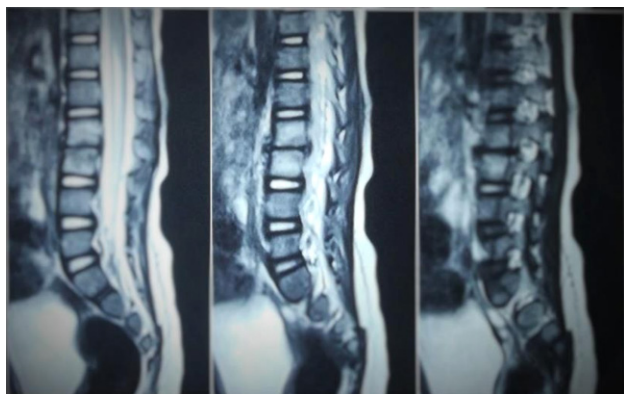


Figure 1. MRI L-S Spine showing L2-L3 narrowing and diffuse marrow edema

tendon reflexes were exaggerated. All other systems were within normal limits. Initial lab investigations revealed normal total leucocyte count. CBNAAT test for tuberculosis and mantoux were negative. The blood culture obtained on admission was negative. On further evaluation with series of radiological imaging X-ray of L.S spine revealed gross narrowing of L2-L3 space with irregular endplate margin. MRI spine revealed diffuse marrow edema of L2-L3 vertebral bodies with reduced L2-L3 disc height and minimal soft tissue edema in psoas muscle (**Figure 1**).

Serological workup showed positive ELISA Brucella antibodies IgM titer 1.20 (Positive =>1.1).

USG abdomen was done showed no hepatosplenomegaly. ECHO was done to rule out infective endocarditis,

Child was started on treatment with IV amikacin for 10 days, oral Rifampicin for 6 months and oral Cotrimoxazole for 6 weeks. A repeat MRI was done after completion of 4 weeks of treatment showed status quo. However, repeat imaging after 8 weeks revealed regression of the disease and child showed clinical improvement. Regular follow up on OPD basis showed complete clinical and radiological recovery after 6 months.

DISCUSSION

Brucellosis is a re-emerging worldwide zoonosis and has been reported in at least 56 countries; but it is mainly prevalent in Mediterranean basin, Arabian peninsula, Indian subcontinent, Mexico and Central and South America. *Brucella abortus*, *B.suis* and *B.melitensis* are the common human pathogens No predisposition is found for age groups, sexes or targeted system.¹

In addition to a collection of somatic nonspecific com-

plaints such as fever, sweats, anorexia, fatigue, weight loss, symptoms and signs related to a single system occasionally predominate when the disease is localized.² Osteoarticular involvement in brucellosis includes spondylitis, osteomyelitis, peripheral arthritis, bursitis, and tenosynovitis affecting majority of the patient. The regional distribution of the spondylitis lesions shows a predilection to the lumbar spine (L-4 mostly).³ Clinically, back pain is the most common symptom in patients with spinal involvement, as seen in this case, due to invasion of the richly innervated periosteum.²

Patient should at least have two of the following findings: (1) Blood and/or bone marrow aspirate culture positive for *Brucella*, (2) *Brucella* IgM antibody positivity (3) *Brucella* agglutination titer of 1:160 or higher, Diagnosis of brucellosis is established by compatible clinical picture with demonstration of IgM antibody or four fold rise in antibody titre. (4) Bone scan, radiographs and/or a tomography scan showing skeletal involvement characteristic of osteomyelitis and (5) Positive biopsy finding demonstrating non caseating granulomatous tissue. MR imaging is the method of choice for the diagnostic assessment and follow-up of the spinal brucellosis.³ Lumbar vertebrae are more frequently involved. MRI is more sensitive than radiographs especially in detecting acute sacroiliitis and hip involvement.

The successful treatment of brucellosis requires prolonged chemotherapy regimen with a combination of antibiotics. WHO guidelines recommends two regimens, both involved doxycycline for 6 weeks (since the patient is 2 year old child Doxycycline was not given) in combination with either streptomycin for 2-3 weeks or other Aminoglycosides and Rifampicin for 6 weeks. Trimethoprim- sulfamethoxazole also used. The eradication of infection from the bone is difficult and relapse may occur especially if only short-term treatment is given. Hence, long-term anti-brucellar antibiotic treatment should be prescribed immediately after the diagnosis.²

Because of the ambiguous nature of the clinical signs and symptoms of brucellosis, the disease is often misdiagnosed as tuberculosis.⁶ Studies are ongoing to develop an effective vaccine against *B.suis*.⁷ Till then the lack of human vaccines and effective control measures make it necessary to practice high clinical suspicion especially where there is a strong contact or travel history to endemic region.⁴ In conclusion; in endemic regions, *Brucella* spondylodiscitis should be considered in patients with back pain with or without neurological deficits. Early and rapid diagnosis and long term anti-

brucellar antibiotic treatment gives better response and complete recovery.

END NOTE

Author Information

1. Dr. M.M Ramdas, Department of Pediatrics, E.M.S Memorial Co-operative Hospital and Research Centre, Perinthalmanna, Malappuram, Kerala, India.
2. Dr. Nihala N K, Department of Pediatrics, E.M.S Memorial Co-operative Hospital and Research Centre, Perinthalmanna, Malappuram, Kerala, India.
3. Dr. Jayakrishnan, Department of Neurosurgery, E.M.S Memorial Co-operative Hospital and Research Centre, Perinthalmanna, Malappuram, Kerala, India.
4. Dr. Manuel J, Department of Orthopedics, E.M.S Memorial Co-operative Hospital and Research Centre, Perinthalmanna, Malappuram, Kerala, India.

Conflict of Interest: None declared

REFERENCES

1. Gokhale YA, Ambardekar AG, Bhasin A, Patil M, Tillu A, Kamath J. Brucella spondylitis and sacroiliitis in the general population in Mumbai. *J Assoc Physicians India.* 2003;51:659-66.
2. Ali R, Salman JA, Shaikh OA, Abdulla F, Oraibi AA. Brucellosis with spondylitis. *Bahrain Med Bull.* 2007;29(4):1-4.
3. Hantzidis P, Papadopoulos A, Kalabakos C, Boursinos L, Dimitriou CG. Brucella cervical spondylitis complicated by spinal cord compression: a case report. *Cases J.* 2009;2:6698.
4. Smits HL, Kadri SM. Brucellosis in India: a deceptive infectious disease. *Indian J Med Res.* 2005;122(5):375-84.
5. Bukharie HA. Clinical features, complications and treatment outcome of Brucella infection: ten years' experience in an endemic area. *Trop J Pharm Res.* 2009;8(4):303-10.
6. Dewan E, Oberoi A, John B, Mathias A, Abraham D. Brucellar spondylodiscitis mimicking tuberculosis. *CHRISMED J Health Res.* 2015;2(3):294-7.
7. Mantur BG, Amarnath SK, Shinde RS. Review of clinical and laboratory features of human brucellosis. *Indian J Med Microbiol.* 2007;25(3):188-202.